

Association between vitamin-D deficiency with the presence and severity of diabetic retinopathy in type-2 diabetes mellitus

Sanhita Mukherjee¹ and Kumares Chandra Sarkar^{2*}

¹Department of Physiology, Calcutta National Medical College, 32 Gorachand Road, Kolkata-700014 West Bengal, India and ²Department of Ophthalmology, Calcutta National Medical College, 32 Gorachand Road, Kolkata-700014 West Bengal, India

Received: 18th October 2019; Accepted: 26th December 2019; Published: 01st January 2020

Abstract: *Introduction:* Several previous studies shown that vitamin D deficiency is highly prevalent in type 2 diabetes mellitus. Vitamin D has inhibitory effects on inflammation and angiogenesis, which are involved in the development of DR. *Objective:* To find an association with 25 (OH) Vitamin D levels and Diabetic retinopathy (DR) and also to explore whether any relationship exists between 25 (OH) Vitamin D level and degree of severity of Diabetic Retinopathy. *Methods:* 58 Type 2 DM patients [32 cases with Diabetic Retinopathy and 26 Control with out Diabetic Retinopathy] were evaluated for their ophthalmic findings, glycaemic status and 25 (OH) Vitamin D levels. They were further sub-divided into Patients with No Retinopathy, Mild to Moderate Retinopathy and Severe Retinopathy. Chi square test, Student t test, ANOVA, Relative Risk and Multivariate logistic regression analysis were performed and a significance level of 0.05 was used. *Results:* Patients with retinopathy had longer diabetes duration and significantly low 25 (OH) Vitamin D level (p value 0.005364*, 0.002454* respectively) although age of the patients in years showed no significant relationship with retinopathy (p value 0.392599). There is significant inter-group variation in 25 (OH) Vitamin D level among no Retinopathy, mild-moderate Retinopathy and severe Retinopathy group (p value 0.00012*). Patients with 25 (OH) Vitamin D deficiency shows significantly higher risk of developing DR [RR2.70, 95% CI (1.38-4.64), p value: 0.0025] and 25 (OH) Vitamin D level is an independent predictor of DR (p value 0.00027*) but duration of type 2 DM in months is not (p value 0.98). *Conclusion:* Type 2 DM patients with retinopathy were found to have significant vitamin D deficiency as compared to those without retinopathy.

Keywords: Type 2 Diabetes Mellitus, Diabetic Retinopathy, Vitamin D.

Introduction

Diabetic retinopathy (DR) is one of the leading causes of blindness worldwide [1]. It is thought that at 20 years after diabetes onset, nearly all patients with diabetes Type I and 60% of those with diabetes Type II will have evidence of DR on examination [2]. Major risk factors for DR include a longer diabetes duration, age, smoking, poor glycemic control and hypertension, which have been strongly and consistently associated with DR across populations [3].

DR, characterized as a neurovascular disease entity, results from hyper-glycemia-induced changes to the blood-retinal barrier and retinal vasculature. The disease initially presents as a non-neovascular form, or non-proliferative diabetic retinopathy (NPDR). Increasing damage

to the retinal vasculature results in vessel leakage and diabetic macular oedema, and subsequent vascular sclerosis results in ischemia, angiogenesis, and, eventually, retinal neo-vascularization, or proliferative diabetic retinopathy (PDR) [1].

The potential role of vitamin D in the development of diabetic retinopathy has been a matter of specific interest in recent years. Multiple studies have previously shown that vitamin D deficiency is highly prevalent in type 1 and type 2 diabetes [4]. Recent studies have depicted that Vitamin D has inhibitory effects on inflammation and proliferation in endothelial cells, and angiogenesis, which are involved in the development of DR [5-6]. There is some experimental evidence on the preventive effect of vitamin D in the

development of diabetic retinopathy in a rodent model [7]. In addition, studies have also shown that Vitamin D receptor (VDR) is expressed in retina, and VD has direct inhibitory effects on the development of DR in experimental animal models [8-10]. Albert et al. revealed that Vitamin D inhibits retinal neovascularisation in a mouse oxygen-induced ischemic retinopathy model [11].

Ren et al. revealed that Vitamin D has protective effects on DR by inhibiting vascular endothelial growth factor (VEGF) and transforming growth factor- β 1 (TGF- β 1) in the retinas of diabetic rats [12]. In addition, human genetic studies have shown that polymorphisms of VDR gene are associated with DR [13]. Somerecent epidemiological studies suggested asignificant association between low vitamin D status and increased prevalence of diabetic-microangiopathy [14-16]. Given these associations, we sought to determine the relationship between vitamin D insufficiency and diabetic retinopathy. We also intended to explore whether any relationship exists between Vitamin D level and degree of severity of Diabetic Retinopathy.

Material and Methods

Place of study: Department of Physiology and Ophthalmology of Calcutta National Medical College.

Type of study: Analytical Observational Study, Cross-sectional.

Duration of Study: January 2019 to June 2019.

Participants: 58 Type 2 DM patients were evaluated for their ophthalmic findings and relevant investigations for the evaluation of DR. Out of these 58 patients 32 were cases (Type 2 DM patients with Diabetic Retinopathy) and 26 were Control (Type 2 DM patients without Diabetic Retinopathy). The no background diabetic retinopathy (No BDR) group consisted of subjects with type 2 diabetes but no evidence of diabetic retinopathy, such as microaneurysms, cotton-wool spots, intraretinal haemorrhages, or macular oedema [17-18]. Subjects in the Mild-Moderate severity group or Non-proliferative diabetic retinopathy (NPDR) group had evidence of retinopathy, such as microaneurysms, cotton-wool spots, intraretinal haemorrhages, or macular oedema, but no evidence of retinal or iris

neovascularization [17-18]. The Severe Retinopathy group or PDR (Proliferative Retinopathy) group consisted of subjects with neovascularization on the optic disc, retina, or iris, with or without vitreous haemorrhage or prior Pan-retinal photocoagulation. When the diabetic retinopathy was asymmetric, the subject was assigned to the group corresponding to the eye with the worse retinopathy findings.

Sampling Methods: Institutional ethical committee clearance and informed consent from all the patients were obtained. All patients underwent complete ophthalmic examination including detailed history and Direct Ophthalmoscopy.

Relevant blood investigations including FPS (Fasting Plasma Sugar), PPS (Post prandial plasma sugar), HbA1C (Glycosylated haemoglobin) and Vitamin D were done via an automated competitive immunoassay detected by chemiluminescence. The form of vitamin D measured was 25 (OH) vitamin D total. Patients were labelled as vitamin D sufficient 25(OH)D level \geq 30.0 ng/ml or vitamin D insufficient (25(OH)D < 30.0 ng/ml) [19]. A thorough medical examination was carried out by a physician to rule out any systemic disease.

Inclusion criteria: All patients older than 18 or younger than 90 years of age and confirmed to be Type 2 DM were included in the study.

Exclusion criteria

- 1) Type 1 DM patients
- 2) Younger than 18 or older than 90 years of age
- 3) Any patient with a history of 25 (OH) Vitamin D supplementation, multivitamins containing more than 1000 IU of vitamin D per day, or any medications that could alter vitamin D metabolism, such as rifampicin, phenytoin, or phenobarbital.
- 4) Subjects with prior diseases that suggested baseline alterations in 25 (OH) vitamin D and calcium metabolism, such as hyperparathyroidism or hypoparathyroidism, or recent nephrolithiasis

- 5) Patients who were cognitively impaired or unable to provide written informed consent
- 6) Any Cardiovascular or Renal Disease

Statistical Methods: The statistical analysis was performed by SPSS (Version 18). Retinopathy severity and the dichotomous “retinopathy” (present or absent) served as the primary outcome variables. Student t test has been used to measure the association between the duration of diabetes, age of the patients, HbA1c and 25 (OH) Vitamin D levels with type 2 DM patients having DR (cases) and No DR (Control). Chi-square test was used to study statistical significance of 25 (OH) Vitamin D deficiency in DR patients. The whole group of 58 patients were further sub-divided into Patients with No Retinopathy, with Mild to Moderate Retinopathy and Severe Retinopathy (as per International Clinical Disease Severity Scale for DR [19]).

Analysis of Variance (ANOVA) Test among the above three groups was done to see the correlation between 25 (OH) Vitamin D level and Severity of DR. The relative risk was computed to assess the increased risk of 25 (OH) vitamin D deficiency in patients with retinopathy versus those without this complication. To further analyse the association of retinopathy with 25 (OH) vitamin D logistic regression models were used to assess 25 (OH) vitamin D deficiency, establishing an appropriate threshold in the serum

levels for this purpose. Multivariate regression analyses were performed including disease duration as potential predictors in addition to patient group. A significance level of 0.05 was used.

Results

There were 32 patients with DR (case) and 26 with no DR (control). The demographic characteristics of the cases and control (age in years, Duration of DM in months), their corresponding 25 (OH) Vitamin D level (nano gram /ml) and result of Independent t testis shown in Table-1. The Mean (+/-SD) age of patients with DR was 55.59±8.94 years and that of control was 56.230 ± 8.64. Mean (+/-SD) duration of DM2 in cases was 142.55±84.78 months and in control was 33.6 ±21.46 months. Mean (+/-SD) 25 (OH) Vitamin D level among cases was 20.82± 7.26 nano gram/ml and that of control was 34.57± 14.68 nano gram/ml.

Independent t test showed patients with retinopathy had longer diabetes duration and significantly low 25 (OH) Vitamin D level (p value 0.005364*, 0.002454* respectively) although age of the patients in years and Glycosylated Haemoglobin (HbA1C) showed no statistically significant relationship with retinopathy (p value 0.392599 and 0.78 respectively).

| Table-1: Clinical and Biochemical characteristics of patients with type 2 diabetes with or without retinopathy | | | |
|---|---------------------------------------|--------------------------------|----------------|
| | No Retinopathy/ Control (n=26) | Retinopathy/Case (n=32) | P value |
| Age in Yrs. (Mean+/-SD) | 56.230 ± 8.64 | 55.59±8.94 | 0.392599 |
| Duration of disease in months (Mean+/-SD) | 33.6 ±21.46 | 142.55±84.78 | 0.005364* |
| HbA1C (%) | 5.2±1.2 | 5.5±1.4 | 0.78 |
| Vit D level in nano gm/ml (Mean+/-SD) | 34.57± 14.68 | 20.82± 7.26 | 0.002454* |

Table-2 presents a comparison of the patient with no retinopathy(n=26), mild-moderate retinopathy (n=25) and severe retinopathy (n=7) where 25 (OH) Vit D concentration were either above or below the threshold value 30 ng/ml. 25-(OH) Vitamin D deficiency was observed in 8

(30.76%) No Retinopathy, 20 (80%) Mild-moderate Retinopathy and 5 (71.42%) Severe Retinopathy patients. The difference between the groups was statistically significant (p<0.05; $\chi^2 = 13.381$)

| | No Retinopathy | Mild-Mod Retinopathy | Severe Retinopathy | P value |
|---|----------------|----------------------|--------------------|------------------------------|
| 25 OH Vit D Deficient (<30 nanogram/ml) | 8 (30.76%) | 20 (80%) | 5 (71.42%) | < 0.05, $\chi^2 = 13.381$ |
| 25 OH Vit D not Deficient (>30 nanogram/ml) | 18 (69.23%) | 5 (25%) | 2 (28.57%) | |

Fig-1: Mean values of Vitamin D level in No Retinopathy, Mild Retinopathy and Severe Retinopathy groups

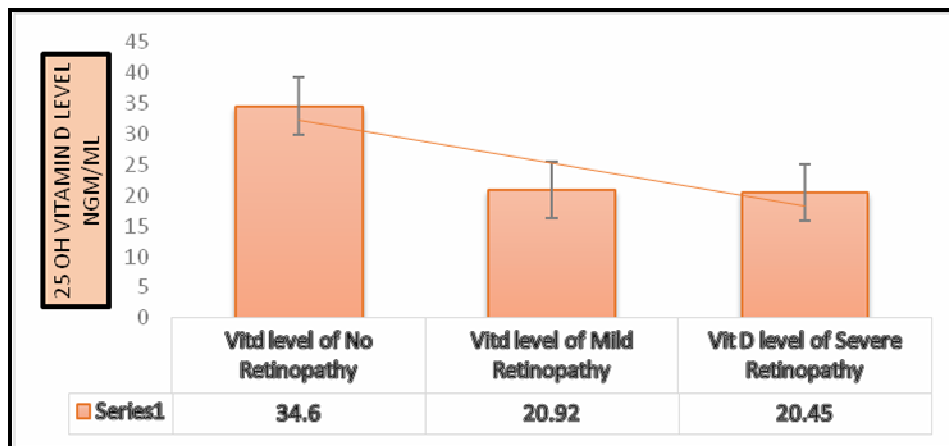


Figure-1 shows gradual increase in mean serum 25 OH Vit D level among No Retinopathy, Mild Retinopathy and Severe Retinopathy groups.

Table-3 depicts Mean± SD of 25 OH Vitamin D level (nano gm/ml) in No Retinopathy, Mild Retinopathy and Severe Retinopathy groups.

Table-4 demonstrates data obtained after ANNOVA. There are significant inter-group variations of 25 OH Vitamin D level among the three groups. (p value 0.00012)

| | Vit D level (nano gm/ml) Mean ±SD |
|--------------------------|-----------------------------------|
| No Retinopathy (n=26) | 30.60±9.98 |
| Mild Retinopathy (n=25) | 20.92±7.17 |
| Severe Retinopathy (n=7) | 20.45±8.53 |

| Source of Variation | SS | df | MS | F | P-value | F crit |
|---------------------|--------|----|--------|--------|---------|---------|
| Between Groups | 2716.3 | 2 | 1358.1 | 10.626 | 0.00012 | 3.16499 |
| Within Groups | 7029.4 | 55 | 127.80 | | | |
| Total | 9745.7 | 57 | | | | |

Table 5 shows Odds Ratio and Relative Risk of Diabetic Retinopathy in Vit D deficient patients. Patients with 25 OH- Vitamin D deficiency

shows significantly higher risk of developing DR. [Odds Ratio 8.035, 95% CI (2.46-26.19), p value: 0.0005].

| Table-5: Odds Ratio and Relative Risk of 25-OH Vitamin D level among Cases (patients with DR) and Control (patients without DR) | | |
|--|-----------------|----------------|
| OR | 95% C. I | p Value |
| 8.035 | 2.46-26.19 | 0.005 |
| RR | 95% C. I | p Value |
| 2.70 | 1.38-4.64 | 0.0025 |

Table 6 shows multiple regression modelling after adjustment for duration of DM2 in months. The model shows 25 OH Vitamin D level is an independent predictor of DR (p value 0.00027*) but duration of DM2 in months is not (p value 0.98). One unit decrease in 25 OH Vitamin D level is expected to increase the risk of DR by 0.017 times.

| Table-6: Multivariate logistic Regression analysis with presence or absence of Diabetic Retinopathy (DR) as Dependent Variable, 25 OD Vitamin D level as Independent variable and duration of DM2 in months as co-variate | | | |
|--|--------------------|-------------------|----------------------|
| Variables | Coefficient | Std. Error | p value(sig.) |
| Constant | 0.895933468 | 0.175951915 | 0.0000047 |
| 25 OH Vitamin D level (x1) | -0.017689389 | 0.004548251 | 0.000273* |
| Duration of DM2 in months (x2) | 0.001193976 | 0.000710667 | 0.098614 |
| Diabetic Retinopathy= 0.895 -(0.176) 25 OH Vitamin D level(nanogram/ml)+ (0.001) Duration of DM2 in months | | | |

Discussion

The present study shows the association of 25 (OH) Vitamin D deficiency with DR in type 2 DM. Furthermore, a higher proportion of 25 (OH) Vitamin D deficiency is confirmed in subjects with severe retinopathy. Although our results are discordant with 2 previous studies that did not show an association of vitamin D with diabetic retinopathy in type2 diabetes [14, 20] our findings are in line with the majority of previous reports that demonstrated association of 25 (OH) Vitamin D deficiency and Diabetic Retinopathy [21-24]. Additionally, it is remarkable that, as in our study, most others have found a relationship between vitamin D status and the severity of retinopathy [21-24].

In our study the patients with retinopathy were found to have longer duration of diabetes mellitus as compared to control. Many other studies have also identified the duration of diabetes as the major risk factor for the development of diabetic retinopathy [25-26]. Shaukat et al also showed positive correlation between the duration of diabetes with the incidence of retinopathy as in current study [27]. In the present study age of the patients in years failed to show any statistically significant relationship with retinopathy which is in contrast to many of the previous reports that depicted age at presentation as a risk factor of diabetic retinopathy [26, 28]. However, a recent

study by Vinícius Carriero Lima and colleague documented that effect of age is a confounding factor but years since DM diagnosis, hypertension, serial high HbA1c levels and male sex were independent risk factors for the development of diabetic retinopathy [29]. Hb A1c level was not significantly different among the retinopathy group and the control in our study (p 0.78). This may indicate both the case (DM2 patients with DR) and control group (DM2 patients without DR) in this study had good glycaemic control.

Our study shows there was an increased risk of retinopathy in those with severe vitamin D deficiency (RR = 2.70, p value = 0.0025). This is also reported by Nuria Alcubierre et al in their study done on European population [30]. In the current study duration of Diabetes and 25 (OH) Vitamin D deficiency, both, showed association with DR. So we did multivariate logistic regression analysis after adjustment for duration of diabetes in months. Interestingly, the regression model showed 25 (OH) Vitamin D level is an independent predictor of DR (p value 0.00027*) but duration of DM2 in months is not (p value 0.98). Hence from this result we can conclude that duration of diabetes is a confounding factor and deficiency of 25 (OH) Vitamin D is an independent risk factor for DR.

Our study shares the most important limitation with previous studies that is, all the studies were cross-sectional. This design allows only for the identification of an association between study variables. Another limitation of our study is that we did not determine the time of sun exposure. Therefore, future studies should include a measure of sun exposure as an essential contributor to 25 (OH) vitamin D concentrations. We should point out that an important strength of the current study is that the patients included did not have important confounding conditions that have an important influence on vitamin D concentrations, that is, renal insufficiency and cardiovascular disease [31-32].

Financial Support and sponsorship: Nil

Conflicts of interest: There are no conflicts of interest.

Conclusion

Our study confirms the association of a higher frequency of vitamin D deficiency and lower concentrations of 25(OH) D with diabetic retinopathy in patients with type 2 diabetes. Further, these parameters of poor vitamin D status are also associated with the severity of diabetic retinopathy. These findings reveal the potential role of vitamin D in the pathogenesis of diabetic retinopathy. However, we need well-designed prospective observational studies sufficiently powered to test the role of vitamin D status in the development of diabetic retinopathy and other diabetic microvascular complications.

References

1. Wan TT, Li XF, Sun YM, Li YB, Su Y. Recent advances in understanding the biochemical and molecular mechanism of diabetic retinopathy. *Biomed Pharmacother.* 2015; 74:145-147.
2. Hendrick AM, Gibson MV, Kulshreshtha A. Diabetic retinopathy. *Prim Care.* 2015; 42:451-464.
3. Dinesh RB, Anil Kumar R. Vitamin D and Diabetic Retinopathy in Indian adults with Type 2 Diabetes Mellitus. *Int J Med Res Rev.* 2018; 6 (04):221-227.
4. Palomer X, Gonz'alez-Clemente JM, Blanco-Vaca F and Mauricio D. Role of vitamin D in the pathogenesis of type 2 diabetes mellitus. *Diabetes, Obesity and Metabolism.* 2008; 10(3):185-197.
5. Robinson JG, Manson JE, Larson J, Liu S, Song Y, Howard BV, Phillips L, Shikany JM, Allison M, Curb JD, Johnson KC, Watts N. Lack of association between 25 (OH) D levels and incident type 2 diabetes in older women. *Diabetes Care.* 2011; 34(3):628-634.
6. Suzuki A, Kotake M, Ono Y, Kato T, Oda N, Hayakawa N, Hashimoto S, Itoh M. Hypo vitaminos is D in type 2 diabetes mellitus: Association with microvascular complications and type of treatment. *Endocr J.* 2006; 53(4):503-510.
7. Ren Z, Li W, Zhao Q, Ma L and Zhu J. The impact of 1,25-dihydroxy vitamin D3 on the expressions of vascular endothelial growth factor and transforming growth factor-1 in the retinas of rats with diabetes. *Diabetes Research and Clinical Practice.* 2012; 98(3):474-480.
8. Zhong X, Du Y, Lei Y, Liu N, Guo Y, Pan T. Effects of vitamin D receptor gene polymorphism and clinical characteristics on risk of diabetic retinopathy in Han Chinese type 2 diabetes patients. *Gene* 2015; 566(2):212-216.
9. Liu Z, Liu L, Chen X, He W, Yu X. Associations study of vitamin D receptor gene polymorphisms with diabetic microvascular complications: a meta-analysis. *Gene* 2014; 546(1):6-10.
10. Ouchi M, West K, Crabb JW, Kinoshita S, Kamei M. Proteomic analysis of vitreous from diabetic macular edema. *Exp Eye Res* 2005; 81(2):176-182.
11. Albert DM, Scheef EA, Wang S, Mehraein F, Darjatmoko SR, Sorenson CM and Sheibani N. Calcitriol is a Potent Inhibitor of Retinal Neovascularization. *Investigative Ophthalmology & Visual Science.* 2007; 48(5): 2327-34
12. Reins RY and McDermott AM. Vitamin D: Implications for Ocular Disease and Therapeutic Potential. *Exp Eye Res.* 2015; 134:101-110.
13. Wu YN, Zhang YP and Wang AP. Association between DNA polymorphism of human Vitamin D receptor (VDR) gene and Type 2 diabetic retinopathy in mongolian people. *Inner Mongolia Medical Journal.* 2010; 42(3):271-274.
14. Patrick PA, Visintainer PF, Shi Q, et al. Vitamin D and retinopathy in adults with diabetes mellitus. *Arch Ophthalmol.* 2012; 130(6):756-760.
15. Aksoy H, Akçay F, Kurtul N et al. Serum 1,25 dihydroxy-vitamin D (1,25 (OH) 2D3), 25 hydroxyvitamin D (25 (OH) D) and parathormonelevels in diabetic retinopathy. *Clin Biochem* 2000; 33(1):47-51.
16. Diaz VA, Mainous AG, Carek PJ, et al. The association of vitamin D deficiency and insufficiency with diabetic nephropathy: implications for health disparities. *J Am Board Fam.* 2009; 22(5):5217.
17. Payne JF, Ray R, Watson DG, Delille C, Rimler E, Cleveland J, Lynn MJ, Tangpricha V, Srivastava SK. Vitamin D insufficiency in diabetic retinopathy. *Endocr Pract.* 2012; 18(2):185-193.
18. Wilkinson CP, Ferris FL, Klein RE, Lee PP, Agardh CD, Davis M, Dills D, Kampik A, Pararajasegaram R, Verdager JT. Proposed international clinical diabetic retinopathy and diabetic macular edema disease severity scales. *Ophthalmology.* 2003; 110:1677-1682.

19. Bischoff-Ferrari HA, Giovanucci E, Willett WC, Dietrich T, Dawson-Hughes B. Estimation of optimal serum 25-hydroxyvitamin D for multiple health outcomes. *Am J Clin Nutr.* 2006; 84:18-28.
20. Joergensen C, Reinhard H, Schmedes A et al. Vitamin D levels and asymptomatic coronary artery disease in type 2 diabetic patients with elevated urinary albumin excretion rate. *Diabetes Care,* 2012; 35(1):168-172.
21. Payne F, Ray R, Watson DG. Vitamin D insufficiency in diabetic retinopathy. *Endocrine Practice,* 2012; 18(2):185-193.
22. Ahmadieh H, Azar ST, Lakkis N and Arabi A. Hypovitaminosis D in patients with type 2 diabetes mellitus: a relation to disease control and complications. *ISRN Endocrinology,* 2013; 1-7.
23. He R, Shen J, Liu F. Vitamin D deficiency increases the risk of retinopathy in Chinese patients with Type 2 diabetes. *Diabetic Medicine,* 2014; 31(12):1657-1664.
24. Jee D, Han KD, Kim EC and Vavvas D. Inverse association between high blood 25-hydroxyvitamin D levels and diabetic retinopathy in a representative Korean population. *PLoS ONE,* 2014; 9(12): 1-17.
25. Takao T, Ide T, Yanagisawa H. The effect of fasting plasma glucose variability and time-dependent glycemic control on the long-term risk of retinopathy in type 2 diabetic patients. *Diab Res Clin Prac.* 2011; e40-e42.
26. Hussain S, Qamar MR, Iqbal MA, Ahmad A, Ehsan Ullah. Risk factors of retinopathy in type 2 diabetes mellitus at a tertiary care hospital, Bahawalpur Pakistan. *Pak J Med Sci* 2013; 29(2):536-539.
27. Shaikat A, Arain TM, Ali I, Alam MF, Sajid MA, Nasreen S. Frequency of retinopathy among adult diabetics in Bahawalpur City. *Pak J Pathol.* 2011; 22(2):53-57.
28. Anwar SB, Asif N, Naqvi SAH, Malik S. Evaluation of multiple risk factors involved in the development of Diabetic Retinopathy. *Pak J Med Sci.* 2019; 35(1):156-160.
29. Lima VC, Cavalieri GC, Lima MC, Nazario NO and Lima GC. Risk factors for diabetic retinopathy: a case-control study. *Int J Retin Vitro,* 2016; 2:21.
30. Alcubierre N, Valls J, Rubinat E, Cao, Esquerda A, Traveset A, Granado-Casas M, Jurjo C and Mauricio D. Vitamin D Deficiency is Associated with the Presence and Severity of Diabetic Retinopathy in Type 2 Diabetes Mellitus. *Journal of Diabetes Research,* 2015; 1-6.
31. Vinagre I, Mata-Cases M, Hermosilla E et al. Control of glycemia and cardiovascular risk factors in patients with type 2 diabetes in primary care in Catalonia (Spain). *Diabetes Care,* 2012; 35(4):774-779.
32. Kienreich K, Tomaschitz A, Verheyen N. Vitamin D and cardiovascular disease. *Nutrients,* 2013; 5(8):3005-3021.

Cite this article as: Mukherjee S and Sarkar KC. Association between vitamin-D deficiency with the presence and severity of diabetic retinopathy in type-2 diabetes mellitus. *Al Ameen J Med Sci* 2020; 13(1): 10-16.

This is an open access article distributed under the terms of the Creative Commons Attribution-Non Commercial (CC BY-NC 4.0) License, which allows others to remix, adapt and build upon this work non-commercially, as long as the author is credited and the new creations are licensed under the identical terms.

*All correspondences to: Dr. Kumaresh Chandra Sarkar, Associate Professor, Department of Ophthalmology, Calcutta National Medical College, 32 Gorachand Road, Kolkata-700014 West Bengal, India. E-mail: drkumareshcs@gmail.com